

Metallic hair pin aspiration into the left tertiary bronchus

Noh KB, Salim R, Abdullah MS, Mohamad I

Noh KB, Salim R, Abdullah MS, et al. Metallic hair pin aspiration into the left tertiary bronchus. *Malays Fam Physician*. 2018;13(2):36–38.

Keywords:

Foreign body aspiration;
tertiary bronchus;
bronchoscopy; fluoroscopy

Authors:

Khairul Bariah Noh

(Corresponding author)
Department of Otorhinolaryngology -
Head & Neck Surgery
School of Medical Sciences
Universiti Sains Malaysia Health
Campus, 16150 Kota Bharu
Kelantan, Malaysia.
Email: siskik85@gmail.com

Rosdan Salim

Department of Otorhinolaryngology -
Head & Neck Surgery
School of Medical Sciences
Universiti Sains Malaysia Health
Campus, 16150 Kota Bharu
Kelantan, Malaysia.

Mohd Shafie Abdullah

Department of Radiology, School of
Medical Sciences, Universiti Sains
Malaysia Health Campus, 16150
Kota Bharu, Kelantan
Malaysia.

Irfan Mohamad

School of Medical Sciences,
Universiti Sains Malaysia Health
Campus, 16150 Kota Bharu
Kelantan, Malaysia.

Abstract

Foreign body aspiration is commonly described in infants and children. However, recently, a new high-risk group was identified among young women, especially those from the Muslim population who wear the traditional hair scarf. This is due to the habit of holding the scarf pin in between the lips to free hands to adjust the scarf more easily. Talking, laughing, or coughing while fixing the scarf may result in inadvertent inhalation of the pin into the tracheobronchial tree. We present a case of scarf pin inhalation and the challenges encountered in managing this patient during the successful removal of the pin via flexible bronchoscopy under fluoroscopy guidance. This particular case was technically challenging for us as the sharp tip of the needle was pointing upward and piercing the bronchial mucosa.

Introduction

Tracheobronchial foreign body aspiration is a nightmare and can result in life-threatening complications, especially among children. Although it is rare in adults, the incidence is known to increase with advancing age.¹ This is due to the failure of airway protective mechanisms as an adult age.

However, nowadays, incidences are being reported in young Muslim women which involve the aspiration of hair scarf pins as a result of careless handling.²

Clinical presentation may vary depending on the site the foreign body has embedded in. Removal of a sharp foreign body is technical challenging and needs urgent attention. Locating the sharp end of the hair scarf pin is the key to removing this type of foreign body.³

Case Report

A 35-year-old lady was referred from a private hospital for further management of a foreign body lodged in the bronchus. She had held a scarf pin between her lips in order to have both hands free while fixing her head scarf, but she allegedly accidentally aspirated the foreign body after coughing suddenly. A few minutes after that, she started to have mild discomfort on the left side of her chest, especially while talking and taking a deep breath. Otherwise there was no hoarseness,

fever, shortness of breath, dysphagia, or other obstructive symptoms.

Clinically, the patient was comfortable with stable vital signs. On auscultation, air entry was equal for both lungs.

A chest radiograph (AP view) revealed a radio-opaque foreign body measuring 4 cm in length, which was vertically located in the left lung field (**Figure 1**). No pneumothorax was detected.

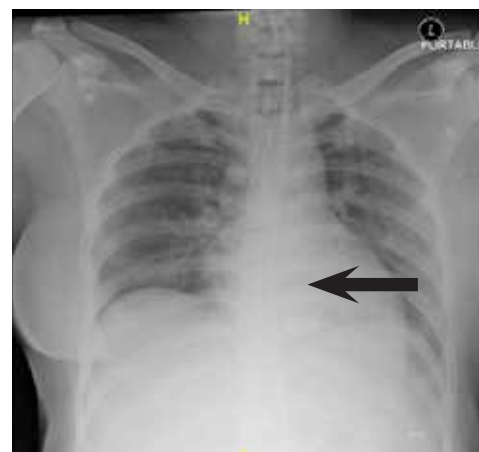

Figure 1: Radio-opaque foreign body, approximately 4 cm in length, towards left side of lung field (see arrow)

Patient was posted for emergency foreign body removal under general anesthesia (GA). Rigid and flexible bronchoscopy was performed. Intraoperative findings showed that the metal pin was located at

the left lower tertiary bronchus and was half-embedded in the bronchial wall. As the tip of the pin was embedded in the mucosa, multiple attempts to remove the pin were fruitless. After struggling for many hours, the procedure was abandoned.

Computed tomography (CT) of the thorax was then arranged after discussion with a team of interventional radiologists to locate the tip of the pin and rule out migration of the foreign body. The CT scan revealed that the tip of the pin was embedded approximately 1 cm into the bronchial septum. The head of the pin was pointed inferomedially at the left tertiary bronchus, making the attempt to grab the distal end extremely very difficult (Figure 2).

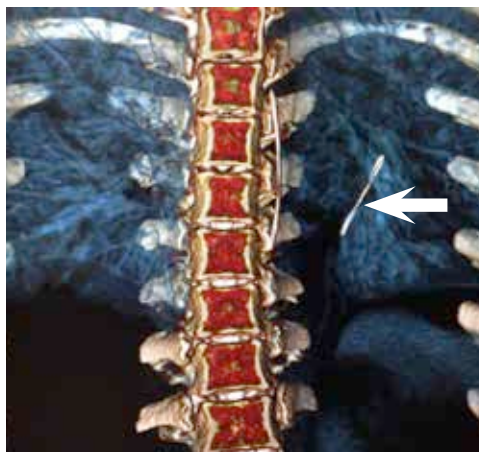


Figure 2: Computed tomography image reconstruction of thorax. Note the head of the pin pointed inferomedially at the left tertiary bronchus.

We proceeded with flexible bronchoscopy and foreign body removal under GA with a combined otorhinolaryngology (ORL) and radiology team and a cardiothoracic surgeon standing by. An angiocatheter was inserted through the flexible bronchoscopy side port under fluoroscopy guidance. An attempt to remove the pin using a snare was unsuccessful. The tip of the pin was accidentally dislodged by manipulation of the angiocatheter, then later grabbed by flexible optical forceps and removed as a whole together with the bronchoscopy without any significant trauma. A chest radiograph was performed after the procedure and showed no evidence of pneumothorax.

The procedure was uneventful, and the patient was discharged home after 48 hours of observation. Further follow-up reassured us that the patient was well.

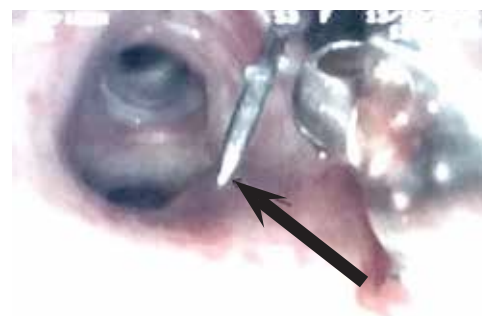


Figure 3: Endoscopic view of the tip of the pin after it was dislodged by the angiocatheter




Figure 4: The scarf pin, approximately 4 cm in length, that was removed.

Discussion

Tracheobronchial foreign body aspiration is uncommon among the adolescent population. Head scarf pin aspiration is more common in the Middle Eastern population. To our knowledge, this is first reported case of head scarf pin aspiration in Southeast Asia. A few cases of scarf pin inhalation have been previously reported in Jordan, Egypt, and Turkey.

The most important thing in the diagnosis of foreign body inhalation is the history. The presenting symptoms depend on the location of the foreign body. Most of the cases of tracheobronchial foreign body inhalation are asymptomatic. The most common site of aspiration is on the right side, which covers approximately 70% of all cases in view of its anatomical structure, which is more vertical.⁴ However, in our case, the foreign body was located on the left side. The preference of this particular pin to lodge on the left side can be explained by the Bernoulli phenomenon.⁵ Negative pressure after laughing, coughing, or speaking, along with the relatively narrow diameter of the left bronchus compared to the right, allows more negative suction pressure to be gained in the left bronchial tree, which, in this case, allowed the pin to travel to the left side.

The other problem encountered in our case was the difficulty in locating the tip of the pin, which was embedded in the mucosa of the bronchus. Failure to grab the tip of the pin led to the failure of our multiple attempts. The embedded tip of such a sharp end can cause complications, such as erosion of the mucosal wall leading to a mucosal tear. Other complications of embedded head scarf pin previously reported are obstructive emphysema (2%), bronchiectasis (4%), pulmonary abscess (2%), pneumothorax (1%), mediastinitis (2%), hemorrhage (1%), and arrhythmia (3%).^{6,7}

Plain radiograph is a diagnostic tool for radiopaque foreign bodies or pneumothorax. However, CT scanning demonstrated a better anatomical image, showing the characteristics of the foreign body and suggesting possible means of collection.⁸ Thus, it became a very significant imaging modality in our case.

The choice between using a flexible or a rigid bronchoscope is still controversial, although the rigid variety is in wider use. Rigid bronchoscopy provides excellent visualization and allows for continuous ventilation of the patient. However, for the past few decades, flexible bronchoscopy has been advocated as the primary diagnostic and therapeutic modality for management of tracheobronchial foreign body aspiration, with reported success rates exceeding 90%.⁹ In our case, the use

of flexible bronchoscopy with fluoroscopy guidance was preferred in view of the location of the pin in the tertiary bronchus. We would have been unable to reach the site of the foreign body using rigid bronchoscopy. Using rigid bronchoscope in tertiary bronchus is an intrusive examination that can contribute additional complications.¹⁰

Multidisciplinary teamwork between the ORL surgeon, anesthetist, radiologist, and cardiothoracic surgeon was needed in our case. Sharing knowledge and experiences contributed to the successful removal of foreign body and shortened the operative time. Failure to remove this foreign body would have resulted in increasing morbidity for this patient, possibly requiring a thoracotomy with a lobectomy.¹¹

Conclusion

It is important to advise all women to avoid holding a pin between their lips while fixing their head scarf to prevent inhalation. A CT scan is a gold standard procedure for identifying the nature, position, and orientation of a pin. A multidisciplinary approach is important when managing this type of case in order to remove the foreign body as early as possible to prevent possible complications.

Conflict-of-interest statement: All authors have no conflict of interest in this case report.

References

- Boyd M, Chatterjee A, Chiles C, et al. Tracheobronchial foreign body aspiration in adults. *South Med J*. 2009; 102(2): 171-4.
- Rizk N, Gwely NE, Biron VL, et al. Metallic hairpin inhalation: a healthcare problem facing young Muslim females. *J Otolaryngol Head Neck Surg*. 2014; 43(1): 1.
- Mehta AC, Rafanan L. Extraction of airway foreign body in adults. *J Bronchol*. 2001; 8(2): 123-31.
- Rafanan AL, Mehta AC. Adult airway foreign body removal: what's new? *Clin Chest Med*. 2001; 22(2): 319-30.
- Van Looij MA, Rood PP, Hoeve LJ, Borgstein JA. Aspirated foreign bodies in children: why are they more commonly found on the left? *Clin. Clin Otolaryngol Allied Sci*. 2003; 28(4): 364-7.
- Hainer F, Klaub W, Wunsch L, et al. The turban pin aspiration syndrome: Awareness for a subtype of foreign body aspiration. *J Pediatr Surg Case Reports*. 2016; 7:28-30.
- Suleman A, Ikramullah Q, Ahmed F, et al. Indications and complications of bronchoscopy: an experience of 100 cases in a tertiary care hospital. *J Postgrad Med Inst*. 2011; 22 (3): 210-4
- Ragab A, Ebied OM, Zalat S. Scarf pins sharp metallic tracheobronchial foreign bodies: presentation and management. *Int J Pediatr Otorhinolaryngol*. 2007; 71(5): 769-73.
- Al Bshabshe AA. A rare case of tracheobronchial foreign body aspiration in an adult patient admitted to the ICU: A case report and review of the literature. *J Taibah Univ Med Sc*. 2016; 11(3): 274-6.
- Cavel O, Bergeron M, Garel L, et al. Questioning the legitimacy of rigid bronchoscopy as a tool for establishing the diagnosis of a bronchial foreign body. *Int J Pediatr Otorhinolaryngol*. 2012; 76(2): 194-201.
- Thakur A, Kaur K, Jain G, et al. Retrieval of surgical blade by open thoracotomy-A case report of an iatrogenic complication. *Egypt J Anesth*. 2014; 30(4): 447-9.