

Coughing on palpation: A rare complication of vagal schwannoma

Samarakkody ZM, Sayuti KA, Mat Zin AA, Wan Abdul Wahab WNN, Mohamad I

Samarakkody ZM, Sayuti KA, Mat Zin AA, et al. Coughing on Palpation: A Rare Complication of Vagal Schwannoma. *Malays Fam Physician*. 2018;13(3); 40–43.

Keywords:

Vagal schwannoma,
Parapharyngeal, Cough,
Neck mass

Authors:

Zabrina Marnel Samarakkody

(Corresponding author)
(MD)
Department of Otorhinolaryngology
– Head and Neck Surgery
Universiti Sains Malaysia Health
Campus, 16150, Kelantan
Malaysia
email: zabrinagill@gmail.com

Khairil Amir Sayuti

(MBCCh) (MMed Radiology)
Department of Radiology,
Universiti Sains Malaysia Health
Campus, Malaysia

Anani Aila Mat Zin

(MD) (MMed Anatomic Pathology)
Department of Pathology, Universiti
Sains Malaysia Health Campus,
Malaysia

Wan Nor Najmiyah Wan Abdul Wahab

(MD) (MMed Anatomic Pathology)
Department of Pathology, Universiti
Sains Malaysia Health Campus,
Malaysia

Irfan Mohamad

(MD) (MMed ORL-HNS)
Department of Otorhinolaryngology
– Head and Neck Surgery
Universiti Sains Malaysia Health
Campus, Malaysia

Abstract

Cervical vagal schwannoma is an uncommon, benign neoplasm. It is usually asymptomatic and presents as a painless, palpable mass in the neck. However, large schwannomas can cause dysphagia, dysphonia or dyspnea as a result of compression. We report a case of an extremely rare complication of vagal schwannoma in which neck palpation induced the patient to cough. As the patient refused any surgical intervention, conservative management was used.

Introduction

A schwannoma is a benign tumor that arises from the Schwann cells. It is a rare, slow-growing lesion.¹ Schwannomas can be classified into intracranial and extracranial schwannomas based on the site of occurrence and may arise from any cranial nerve except the olfactory and optic nerves, as these two nerves are unmyelinated. Intracranial schwannomas are most frequently found in the vestibulocochlear nerve, followed by the glossopharyngeal, accessory and the hypoglossal nerves.²

Extracranial schwannomas are reported to occur in the head and neck region with a frequency of 25–45%. The majority of schwannomas occur in the vagus or sympathetic trunk, which are components of the parapharyngeal space.² Schwannomas are usually asymptomatic and painless, palpable masses in the neck; however, a large schwannoma can produce dysphagia, dysphonia or dyspnea as a result of compression of the adjacent neck structures.³

Case Report

A 74-year-old gentleman complained of a right neck swelling that had been increasing gradually in size for the past 2 years. He had no pain, dysphagia, dyspnea or dysphonia. He also did not complain of any shortness of breath, foul-smelling breath, fever, weight loss or loss of appetite. He had no symptoms of hyperthyroidism or hypothyroidism. Interestingly, he complained of cough whenever the neck mass was touched. The patient was a diabetic with hyperlipidemia and hypertension. He also had a cerebral insult in the

previous year with right hemiparesis which had resolved. He had no history of tuberculosis or any contact with such patients. The patient was a chronic smoker.

The patient was alert and conscious and oriented to time and place. All cranial nerves were intact. The oral cavity and oropharyngeal examination was unremarkable. The neck examination revealed a fullness on the right Level III measuring 4 cm x 3 cm (**Figure 1**). There were no skin changes and the fullness was not tender and soft on palpation. However, during the palpation of the mass, the patient developed bouts of coughing. Otoscopy and nasoendoscopy showed normal findings. On examination of the larynx and hypopharynx, all structures were normal, and the bilateral vocal cords were mobile.

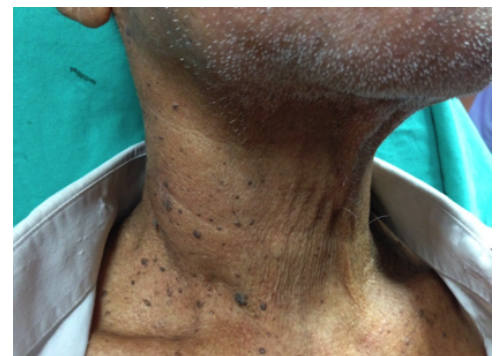

Figure 1. Fullness of the right neck at Level III

A computed tomographic (CT) scan demonstrated a well-defined, solitary mass in the right carotid space, posterior to the carotid artery and internal jugular vein (**Figure 2**). The mass was hypodense to the skeletal muscles

and showed mild enhancement post-contrast. There was no calcification or necrosis within it. The mass measured 2.3 cm x 2.4 cm x 7.6 cm and extended from the level of C2/C3 to C6/C7. It compressed the right internal jugular vein, abutted the common carotid artery and stretched the adjacent sternocleidomastoid muscle. However, the vein was still patent and was not separated from the common carotid artery. These features were suggestive of a right vagal schwannoma.

An attempt to perform fine needle aspiration for cytology (FNAC) failed due to coughing induced by palpation of the mass. In view of risk to the adjacent vascular structures, an ultrasound-guided FNAC was performed with difficulty due to the patient's paroxysmal cough during the procedure. The ultrasound reported a homogenous hyperechoic solid lesion measuring 2.3 cm x 2.6 cm in the right neck lateral to the right internal jugular vein and internal carotid artery. No calcification or vascular activity was noted within it.

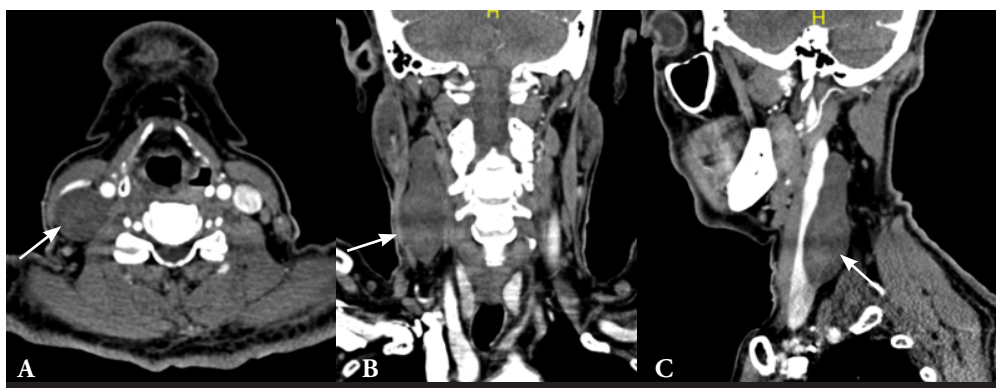


Figure 2. CT scan images in axial (a), coronal (b) and sagittal (c) planes showing a well-defined, mildly-enhanced mass in the right posterior carotid space (white arrow).

Microscopically, the smears of high cellularity were composed of clusters of uniform spindle cells in a bloody background. The spindle cells had oval nuclei, inconspicuous nuclei and a moderate amount of cytoplasm. Blood vessels were also seen intermingled with these clusters. No mitosis or bizarre cells were seen. No lymphoid or squamous elements were noted. Sections from the cell block showed sheets of spindle cells arranged in a hypercellular pattern. Some cells exhibited palisading and formed vague Verrocaey bodies. The fine needle aspirate of the mass showed the presence of spindle cells, indicating that it was most probably a schwannoma.

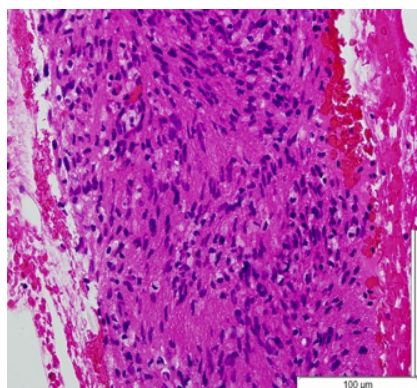


Figure 3: Cell block shows sheets of spindle cells arranged in fascicles. Some of the cells exhibit palisading, forming vague Verrocaey bodies (Hematoxylin & Eosin, x 400 magnification).

Based on the patient's age and co-morbidities, we discussed the treatment plan with the patient and his family. In consideration of the patient's multiple co-morbidities; possible complications, such as hoarseness and injury to the adjacent structures; and the patient's preferences, we agreed to conservative watchful management, as the tumor was benign and slow-growing. As of now, the patient has been under our observation for the past year, tumor growth has been static and no compression symptoms or airway compromise have been exhibited.

Discussion

Schwannoma is a tumor originating from Schwann cells. It can be found in any area of the body. In the head and neck region, tumors have been reported to be in the oral, orbital and nasal cavities, apart from lesions on the scalp mastoid and other upper-airway structures. It can also present as a lateral neck mass, including being found in the parapharyngeal space. The origin of neck schwannomas can be the vagus nerve or the cervical sympathetic chain, i.e., the cervical or branchial plexus.³

Neoplasms of the vagus nerve are rare, and one third of these neoplasms are schwannomas, typically arising from the nodose ganglion. As it exits the skull base, the vagus nerve forms the

superior and the inferior ganglion. Schwannomas are predisposed to grow from the superior ganglion.⁴

The vagus nerve then runs between the internal carotid artery and internal jugular vein within the carotid sheath on the cranial side of the bifurcation of the common carotid artery; later, it then passes between the common carotid and the internal jugular vein on the caudal side. As the vagal schwannoma enlarges, it will displace the internal jugular vein laterally and the common carotid and internal carotid artery medially.^{1,4}

Schwannomas which do not present with a neurological deficit, and a differential diagnosis may be paraganglioma, a branchial cleft cyst, malignant lymphoma or a metastatic cervical lymph node.

Investigations, such as fine needle aspiration and a CT scan, have low specificity and do not allow for differential diagnoses. The better imaging modality is magnetic resonance imaging (MRI).⁵⁻⁷

However, when using a CT scan, if the common carotid and internal jugular veins are separated and displaced antero-laterally, a vagal schwannoma should be suspected. But if the common carotid and internal jugular are not separated, a cervical sympathetic chain schwannoma may be suspected.⁹

Although cough may be a presenting symptom, induced by pressure on the tumor itself, by clothing or via a neck examination, there has been no previously recorded case of coughing being elicited during fine needle aspiration.¹⁰ Although schwannomas are usually asymptomatic, if there are symptoms present, hoarseness is the most common clinical presentation and occasionally a paroxysmal cough may be produced on palpating the mass.¹⁰ A paroxysmal cough during fine needle aspiration is a newly observed symptom.

A paroxysmal or reflex cough is caused by the stimulation of the vagal nerve afferents, similar fashion to the cough elicited by stimulating the Arnold nerve during aural toilet. There have also been reported cases of bradycardia due to the stimulation of the vagal afferents during the excision of a vagal schwannoma, as well.⁶

These symptoms would not be present in a sympathetic chain schwannoma, unless they were

due to pressure on the adjacent structures by the tumor itself. However, a Horner sign can be present due to pressure on the sympathetic chain either by tumor itself or an adjacent tumor.⁸

FNAC is the aspiration of cells or tissue fragments using 22, 23 or 25 gauge needles from palpable lesions. It is a fast, nearly pain-free diagnostic tool. However, it does have its limitations in deep-seated lesions or lesions that are not palpable. This is where ultrasound guidance aided by the radiologist and longer needles play a role. In short, ultrasound-guided fine needle aspiration is an adjunct to plain fine needle aspiration.¹¹

The treatment of choice is essentially surgical, done by intracapsular enucleation of the tumor, preserving the nerve. This surgery is aided by a nerve stimulator and surgical microscope. However, some authors believe that the close adherence of the vagus nerve to the tumor capsule renders preservation of the nerve impossible and advise a complete excision with nerve transection and preferably immediate re-anastomosis or vocal cord medialization.¹² Based on CT imaging alone, it would prove to be difficult to find the plane of dissection to separate out the intracapsular part of the tumor and preserve the nerve. This is due to the close adherence of the tumor capsule to the nerve. As the patient did not consent to surgery, there was no role for the complete excision of the tumor and reanastomosis. Chiofalo et al. mentioned that if it is impossible to find an adequate plane and it is technically difficult to preserve the integrity of the nerve trunk, the involved segment may be resected, and an end-to-end anastomosis could be performed using microsurgical techniques.⁷ Andrea et al. have managed to accomplish end-to-end anastomosis in their series with a resection length of 3 cm and post-operative hoarseness.² Chiofalo et al. also reported that their patient was hoarse post-operatively after a resection of 3 cm as well.⁷ Other literature did not mention the exact length of resections applicable for end-to-end anastomosis.

Prior to 1931, most parapharyngeal schwannomas were excised via the trans-oral route with complications such as incomplete removal, serious hemorrhage, infection and cranial nerve damage.⁸ Nowadays, the trans-cervical surgical approach in the parapharyngeal space is the preferred choice.

Although benign in nature, these schwannomas

may cause pressure on other structures. However, they are relatively radio-resistant.^{8,13} Thus, this modality of treatment is not a viable option.

Some authors advocate a 'wait and see' approach. Asymptomatic tumors can be observed due to their benign nature and indolent course. Their slow growth, low recurrence rate and non-invasive nature often allow for observation.¹²

The malignant potential of extracranial schwannomas and the risk of recurrence after surgical resection are understudied. However, there have been no reports of malignant transformations.⁸

Conclusion

Although rarely encountered in the primary care setting, vagal schwannomas should not be excluded from the list of possible differential diagnoses for a lateral neck mass. Although it is a benign lesion, it can cause local compressive of the neighboring structures manifested as hoarseness, cough or occasionally more distressing symptoms like dyspnea and stridor. A confirmatory MRI and fine-needle aspiration cytology, preferably aided by ultrasonography, are the next management steps. Since a schwannoma is a benign, slow-growing lesion, patients can be observed at 6-month intervals. The treatment of choice is surgery, but the potential morbidities must be discussed well with the patient prior to any invasive treatment.

References

1. Arden RL, Miguel GS. Asymptomatic benign cervical vagal schwannoma: Is there a role for initial observational management? *J Otol Rhinol* 2014;3:4; <http://dx.doi.org/10.4172/2324-8785.1000167>
2. Andrea GD, Fama I, Morello R, et al. Cervical vagal schwannoma, Review of all reported cases and our reports. *Int J Neurol Brain Disord* 2016;3(2): 1- 6.
3. McDermott AM, Sadacharam M. Critical airway compromise due to a massive vagal schwannoma. *Ir Med J* 2016;109(5):408.
4. Sreevatsa MR, Srinivasarao RV. Three cases of vagal nerve schwannoma and review of literature. *Indian J Otolaryngol Head Neck Surg* 2011;63(4):310-312; DOI 10.1007/s12070-011-0220-z.
5. Cavallaro G, Pattaro G, Iorio O, et al. A literature review on surgery for cervical vagal schwannomas. *World J Surg Onco* 2015; 13:130 DOI 10.1186/s12957-015-0541-6.
6. Morrissey MSC, Sellars SL. Vagal nerve schwannoma – a new diagnostic sign. *Postgrad Med J* 1990;66:42-43.
7. Chiofalo MG, Lomgo F, Marone U, et al. Cervical vagal schwannoma. A case report. *Acta Otorhinolaryngol Ital* 2009;29:33-35.
8. Saito DM, Glastonbury CM, El-Sayed IH, et al. Parapharyngeal space schwannomas: Preoperative imaging determination of the nerve of origin. *Arch Otolaryngol Head Neck Surg* 2007;133(7):662-667.
9. Mehta KS, Gupta D, Koul N, et al. Vagal nerve schwannoma - A rare neoplasm with a rare presentation and newer surgical management. *IOSR-JDMS* 2013;9(5):60-65.
10. Sérémé M, Ouédraogo A, Gyébré Y, Ouoba K. Cervical vagal schwannoma: Difficulty of diagnosis and particularity of treatment. *The Internet J Otorhinolaryngo* 2014;16: 1.
11. Gibber MJ, Zevallos JP, Urken ML. Enucleation of vagal nerve schwannoma using intraoperative nerve monitoring. *Laryngoscope* 2012;122:790-792.
12. Williams DB, Sahai AV, Aabekken L, et al. Endoscopic ultrasound guided fine needle aspiration biopsy: A single large centre experience. *Gut* 1999;44:720-726.
13. Yong DJ, Hailani I, Yunus MR. Cervical vagal schwannoma. *Philippine Journal of Otolaryngology Head and Neck Surgery* 2010;25(2):23-26.