

## Acute haemorrhagic oedema of infancy with bullae and koebnerisation

Mohd Sazlly Lim S, Shamsudin N

Mohd Sazlly Lim S, Shamsudin N. Acute haemorrhagic oedema of infancy with bullae and koebnerisation. *Malays Fam Physician* 2014;9(2);55-7

### Keywords:

Acute haemorrhagic oedema of infancy, purpura, leukocytoclastic vasculitis

### Authors:

#### Norashikin Shamsudin

(Corresponding author)  
MRCP, Adv MDerm  
Department of Medicine, Faculty of Medicine and Health Sciences, Universiti Putra Malaysia, 43400 Serdang, Malaysia  
Email: shikin@upm.edu.my

#### Sazlyna Mohd Sazlly Lim

MBBS, MRCP  
Department of Medicine, Faculty of Medicine and Health Sciences, Universiti Putra Malaysia, 43400 Serdang, Selangor, Malaysia

### Abstract

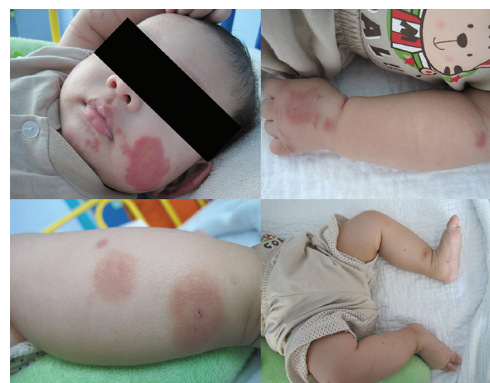A 5-month-old Malay boy presented with purpuric papules and plaques on the face and extremities accompanied by fever, coryzal symptoms and bilateral lower limb oedema. There were also bullous linear purpuric lesions on the right upper limb. Blood and culture tests were normal. Histopathological tests showed leukocytoclastic vasculitis, confirming the diagnosis of acute haemorrhagic oedema of infancy. The patient achieved complete recovery after 2 weeks with no recurrence.

### Introduction

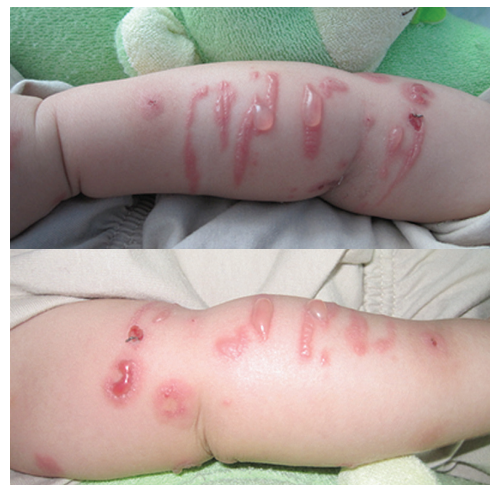Acute haemorrhagic oedema of infancy (AHEI) is a benign form of cutaneous leukocytoclastic vasculitis, which affects children younger than 2 years old. It presents with fever, peripheral oedema and purpuric targetoid plaques on the face and extremities. Despite the dramatic cutaneous presentation, gastrointestinal or renal involvement is uncommon.<sup>1</sup> The disease follows a benign, self-limiting course usually without any recurrence or long term complication. It may be difficult to diagnose, therefore, referral to a specialist for further improvement, observation and management is advisable.

### Case report

A 5-month-old Malay boy presented with fever for 4 days duration accompanied by cough, loose stool, purpuric skin lesions and bilateral lower limb swelling. Three days prior to the onset of illness, the child received his third dose of diphtheria, tetanus and polio (DTP) vaccination. Before coming to the hospital, his mother had brought him to a general practitioner who prescribed him antipyretics and antimicrobials. The skin lesions appeared prior to the commencement of antimicrobials. Starting with purpura on the right ear pinna, the lesions rapidly extended to the upper and lower limbs and finally the face. Papules on the cheeks and lower legs quickly evolved into large and tender plaques. The child had no symptoms of irritability and there was neither haematuria nor haematochezia. He had no known medical illness and had a normal birth history. No other siblings were similarly affected.

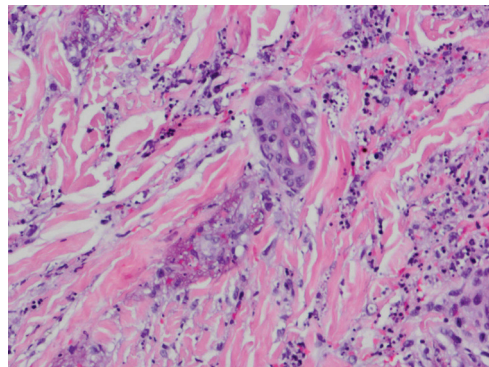


**Figure 1.** Erythematous, non-blanching and indurated papules and plaques on the cheeks, left hand dorsum and bilateral lower limbs



**Figure 2.** Clear and haemorrhagic blisters on linear erythematous plaques encircling the right upper limb

Laboratory investigations were non-specific with normal complete blood count, renal profile, liver function test, anti-streptolysin O titre, complements, immunoglobulin levels, anti-nuclear antibody, anti-mycoplasma IgM and urinalysis. Erythrocyte sedimentation rate (ESR) and C-reactive protein (CRP) were 96 and 28 mg/L respectively. Blood and blister fluid cultures were negative for bacterial growth. A punch biopsy taken from a purpura on the left forearm demonstrated a perivascular neutrophilic infiltration with some eosinophils, extravasated red blood cells and nuclear dusts surrounding the blood vessels, as well as thrombosed vessels. All of these were the features of leukocytoclastic vasculitis (Figure 3). No organisms were seen with PAS (periodic acid—Schiff) and Giemsa histochemical stains. Immunofluorescence study was not done. The clinical features with the skin histopathological findings strongly support the diagnosis of acute haemorrhagic oedema of infancy.



**Figure 3.** High power examination shows small-vessel leukocytoclastic vasculitis in which there is fibrinoid necrosis of the vessel walls, neutrophils infiltrating the vessel walls with nuclear dusting and red cell extravasation (Hematoxylin and eosin (HE) stain, magnification 40\*)

Normal saline wet dressing was commenced on the right upper limb blisters along with 0.025% betamethasone cream for the purpuric plaques. He was discharged after 5 days of admission and at that point the purpuric plaques had already become dusky. On a follow-up visit to the dermatology clinic 2 weeks later, almost all skin lesions had completely cleared without hyperpigmentation or scar. Bullous lesions on the right upper limb; however, had resolved with hyperpigmentation.

### Discussion

AHEI is a form of cutaneous leukocytoclastic vasculitis, occurring in infants younger than 2 years of age.<sup>1-3</sup> Over 250 cases have been reported worldwide but the exact

incidence is unknown. A systematic review reported that 80% of cases occurred in children aged 6–24 months.<sup>4</sup> Its aetiology is unknown, although a history of recent upper respiratory infection, otitis media, pharyngitis, pneumonia, conjunctivitis, urinary tract infection or immunisation has been found in patients.<sup>2,4,5</sup> AHEI has been reported to be associated with viral infections (coxsackievirus,<sup>2</sup> cytomegalovirus,<sup>1</sup> rotavirus<sup>2</sup> and hepatitis A(6)), bacterial infections (*Escherichia coli*, *campylobacter*,<sup>2</sup> streptococcal<sup>4</sup> and staphylococcal<sup>5</sup>), vaccination (measles,<sup>7</sup> diphtheria–pertussis, tetanus or combined)<sup>4</sup> or drug intake (penicillin, cephalosporins, trimethoprim sulphamethoxazole, paracetamol, cough syrup or a combination of these).<sup>2,4,5</sup> Patients typically present with purpuric, targetoid, or rosette-shaped lesions, often found on the head, ears, and limbs together with tender, non-pitting oedema and fever.<sup>8</sup> The trunk and mucous membranes are usually spared.<sup>5</sup>

In terms of laboratory investigations, elevated total white cell count, ESR or CRP can be seen; although no consistent laboratory findings have been reported.<sup>5</sup> Histopathological examination typically shows a leukocytoclastic vasculitis of the dermal vessels with fibrinoid necrosis, extravasation of red blood cells and leucocytoclasia with perivascular IgA deposits in one-third of AHEI cases. Immunofluorescence study also detected IgM and C1q.<sup>1,2,5</sup> According to the clinical presentations alone, it is essential to exclude conditions such as Henoch-Schönlein purpura (HSP), meningococcaemia and erythema multiforme. Other differential diagnoses of AHEI include Sweet syndrome, Kawasaki disease, skin lesions in septicemia or a drug eruption.<sup>1-3,5</sup>

It is possible that the DTP vaccination had induced the disease in the patient—an association previously reported in the literature.<sup>9</sup> Notification of this adverse drug reaction to the Malaysian Adverse Drug Reactions Advisory Committee is also advised if any drug or vaccine is suspected to be the cause. It is unclear how vaccination can cause leukocytoclastic vasculitis but it may be related to hypersensitivity to circulating immune complexes containing viral antigens or any of the preservatives.<sup>10</sup>

The patient also presented with unusual features of AHEI by developing new lesions on areas affected by trauma, essentially a Koebner phenomenon. These lesions then progressed to bullous formation. According to our knowledge, koebnerisation of skin

lesions in AHEI has not been described in the medical literature previously. On the other hand, bullous forms of AHEI has been reported.<sup>11</sup> Koebner phenomenon is common in many other dermatological diseases such as vitiligo, verruca vulgaris and lichen planus.<sup>12</sup> A probable theory is that local inflammation predisposes vessels to immune complex and complement aggregation, resulting in the occurrence of new lesions at traumatic sites.<sup>12</sup>

In this patient, a skin biopsy and histological examination of the bullous linear purpuric lesions on the right upper limb was essential for confirmation. It was important to exclude other skin conditions that may coexist and present with linear bullous lesions over site of trivial trauma such as bullous mastocytosis and milder form of epidermolysis bullosa<sup>13</sup>. These were not performed as the parents declined to repeat the surgical procedure.

In cases with extensive bullous lesions, secondary infection of ruptured bullae and infant dehydration could occur necessitating referral to a specialist for hospitalisation and further management.

As with any self-limiting disease, treatment is symptomatic and oral corticosteroids or antihistamines are not absolutely necessary.

Spontaneous recovery occurs within 6–21 days.<sup>4</sup> Our patient did not have any systemic complication and had an uneventful recovery.

### Conclusion

AHEI is an uncommon, benign cutaneous vasculitis in young children. It is important to identify AHEI as the cutaneous lesions do not appear benign. Hence, caution is needed from the primary care perspective.

### Conflict of interest

The authors declare that there are no conflicts of interest.

### Funding

This research received no specific grant from the government or any other funding agency in the public, commercial or not-for-profit sectors.

### Contribution of authors

Norashikin Shamsudin diagnosed and treated the patient and Sazlyna Mohd Sazly Lim conceived the study. Both participated in the interpretation and drafted the manuscript.

## References

1. Kuroda K, Yabunami H, Hisanaga Y. Acute haemorrhagic oedema of infancy associated with cytomegalovirus infection. *Br J Dermatol.* 2002;147:1254–7.
2. Di Lernia V, Lombardi M, Lo Scocco G. Infantile acute hemorrhagic edema and rotavirus infection. *Pediatr Dermatol.* 2004;21(5):548–50.
3. Liu AJW, Hogan P, Nanan R. Acute haemorrhagic oedema of infancy. *Arch Dis Child.* 2006;91(5):382.
4. Fiore E, Rizzi M, Ragazzi M, Vanoni F, Bernasconi M, Bianchetti MG, et al. Acute hemorrhagic edema of young children (cockade purpura and edema): a case series and systematic review. *J Am Acad Dermatol.* 2008;59(4):684–95.
5. Smitt JHS, Vermeer MH, Faber WR. Acute hemorrhagic edema of infancy (AHEI). *Clin Dermatol.* 2002;20(1):2–3.
6. Bozaykut A, Atay E, Atay Z, Ipek IO, Akin M, Dursun E. Acute infantile haemorrhagic oedema associated with hepatitis A. *Ann Trop Paediatr.* 2002;22(1):59–61.
7. Saray Y, Seçkin D, Sarifakioğlu E, Güleç AT, Demirhan B. Acute infantile haemorrhagic oedema: measles vaccination as possible triggering factor. *Acta Derm Venerol.* 2002;82(6):471–2.
8. Millard T, Harris A, MacDonald D. Acute infantile hemorrhagic oedema. *J Am Acad Dermatol.* 1999;41(5 Pt 2):837–9.
9. Krause I, Lazarov A, Rachmel A, Grunwald MM, Metzker A, Garty BZ, et al. Acute haemorrhagic oedema of infancy, a benign variant of leukocytoclastic vasculitis. *Acta Paediatr.* 1996;85(1):114–7.
10. Famularo G, Nicotra GC, Minisola G, De Simone C. Leukocytoclastic vasculitis after influenza vaccination. *J Clin Rheumatol.* 2006;12(1):48–50.
11. Lai-Cheong JE, Banerjee P, Hill V, Kenny P, Ross J. Bullous acute haemorrhagic oedema of skin in infancy. *Clin Exp Dermatol.* 2007;32(4):467–8.
12. Sagi L, Trau H. The Koebner phenomenon. *Clin Dermatol.* 2011;29(2):231–6.
13. Kleewein K, Lang R, Diem A, Vogel T, Pohla-Gubo G, Bauer JW, et al. Diffuse cutaneous mastocytosis masquerading as epidermolysis bullosa. *Pediatr Dermatol.* 2008;28(6):720–5.