

Rhinolith: An important cause of foul-smelling nasal discharge

Yaroko AA, Mohamad I, Hashim HZ

Yaroko AA, Mohamad I, Hashim HZ. Rhinolith: An important cause of foul-smelling nasal discharge. *Malays Fam Physician* 2014;9(1):30-2

Keywords:

nose, foreign body, rhinolith, foul-smelling discharge

Authors:

Ali Ango Yaroko

(Corresponding author)
M.D, M.Med (ORL-HNS)
Department of Otorhinolaryngology-
Head & Neck Surgery, School of
Medical Sciences, Universiti Sains
Malaysia Health Campus, 16150
Kota Bharu, Kelantan.
Email : aliango2002@yahoo.com

Irfan Mohamad

M.D, M.Med (ORL-HNS)
Department of Otorhinolaryngology-
Head & Neck Surgery, Universiti
Sains Malaysia Health Campus,
Kelantan, Malaysia

Hasme Zam Hashim

M.D, M.Med (ORL-HNS)
Department of Otorhinolaryngology-
Head & Neck Surgery, Universiti
Sains Malaysia Health Campus,
Kelantan, Malaysia

Abstract

Rhinoliths result from neglected nasal foreign bodies that gradually increase in size. They are usually discovered incidentally during routine ENT examination or due to the associated symptoms such as nasal obstruction or persistent foul-smelling unilateral nasal discharge. A case of a 14-year-old girl was reported with a year history of the symptom. The foul-smelling nasal discharge noted by her mother was not the main concern to them. She was referred by her primary care physician as she complained of impacted ear wax. However, rhinolith was incidentally found upon routine clinical examination in the ENT clinic and was removed uneventfully.

Introduction

Nasal foreign bodies left in the nasal cavity for several years lead to the formation of rhinoliths. It is the accumulation of calcium, iron, magnesium and phosphorus around a central core¹ with subsequent increase in size. Rhinoliths may be found incidentally during routine clinical examination² usually in the floor of the nasal cavity located halfway between the posterior and anterior nares.³ Rhinoliths do not show any symptoms at an initial stage but may cause minor symptoms⁴ due to their gradual increase in size. However, with significant increase in the size of the rhinolith, nasal discharge and obstruction are observed with the consequent misdiagnosis as rhinitis or sinusitis.⁵ In addition to the unilaterality of the symptoms, other presentations of rhinoliths include epistaxis and erosion of the nasal septum and the medial wall of maxillary sinus and perforation of hard palate.^{6,7}

Case summary

A 14-year-old girl was referred to the ENT clinic by her primary care physician as she complained of impacted wax in her right ear. Her chief complaint was reduced hearing and tinnitus. On further questioning of other possible related symptoms, she admitted to a year history of persistent foul-smelling unilateral nasal discharge, which was also noted by her mother. However, there was no history of nasal block, epistaxis or foreign body in the nose. There was no preceding history of trauma and no associated history of allergy.

Examination of the ears revealed wax in the right ear, which was removed by suction under microscopy. On anterior rhinoscopy, whitish

mass was apparently seen on the floor of the right nasal cavity. Nasoendoscopic examination revealed a mass occupying the space between the inferior turbinate and septum in the right nasal floor (Figure 1). The mass was dark in colour with mucus overlying it. It was stony hard and gritty in consistency on probing. These findings were consistent with right rhinolith. The left nasal cavity was normal. The rhinolith was completely removed by application of local anaesthesia as outpatient (Figure 2). On crushing the rhinolith, no obvious nidus was identified (Figure 3). The patient was then prescribed a course of oral antihistamine and nasal douching.

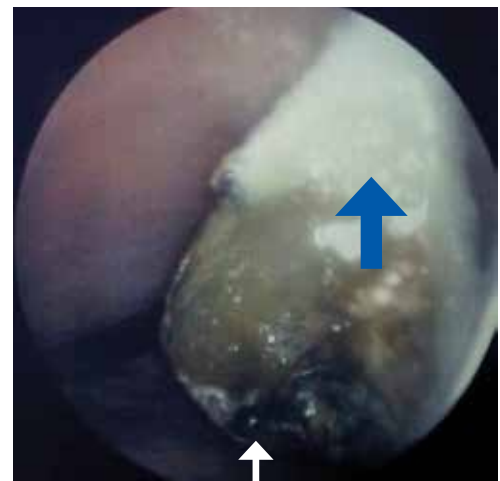

Figure 1. Rhinolith (white arrow) and septum (blue arrow) of the right nasal cavity upon endoscopy

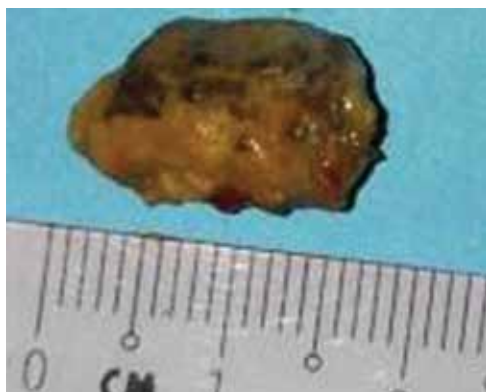


Figure 2. Rhinolith



Figure 3. Crushed rhinolith

Discussion

Rhinolith was first reported by Bartholin in 1654. Polson reported the largest series ever in history consisting of 495 cases.⁷ However, case reports of rhinolith still remain relatively rare in the literature. Although children constitute the majority of patients with different types of nasal foreign bodies, rhinoliths can be seen in patients of all age group especially in young adults.⁶ Rhinoliths are believed to be formed by the deposition of magnesium, iron, calcium and phosphorus around a core, which can be intranasal endogenous or exogenous foreign material.² The endogenous central core could be due to a blood clot, mucus or bone fragment following trauma. An intact deciduous canine tooth found to be the nidus of a rhinolith was reported in a 47-year-old man who presented with clinical features consistent with rhinolith.⁸

The exogenous central cores, which include foreign bodies placed in the nose usually during childhood, are the most common nidus. These foreign bodies usually include beads, buttons, erasers, seeds of fruits, fragments of wood or bone, sand, pieces of paper, and retained nasal packing. Most

commonly, the forgotten foreign body will remain in the nose until patient becomes aware of the foul-smelling unilateral nasal discharge. Irfan et al. (2012) reported a case of a 31-year-old Malay lady who presented with a left nasal blockage for 11 years with findings consistent with rhinolith. It was later identified to be a rubber-tip pencil eraser acting as the core of the rhinolith, isolated from the calcified material upon removal under general anaesthesia.⁹ In our current reported case, no nidus was identified after crushing the rhinolith (Figure 3). In this instance, a blood clot, which might have dissolved, could be the nidus.

Rhinoliths are relatively inert and gradually increase in size; thus they do not show any symptoms at an initial stage but cause minor symptoms once they increase in size.⁴ With significant increase in size over the years, nasal discharge and obstruction are misdiagnosed as rhinitis or sinusitis.⁶ Our index patient presented with foul-smelling nasal discharge that was misdiagnosed over the year as rhinitis. She was later referred to us for a problem of impacted ear wax by her primary care physician. Upon routine ENT examination, the rhinolith was then noted.

Examination of the patient includes anterior rhinoscopy, nasal endoscopy and probing of the mass. In case endoscopy is not available, radiography of the paranasal sinuses may be helpful, although a negative examination will not rule out rhinolith in a symptomatic patient. If diagnosis and extension are not clear, a CT scan can provide accurate details for the location, size and extension of the rhinolith, and any other local diseases that need treatment.¹⁰

Conclusion

Although relatively rare in teenagers and adults, rhinoliths should always be considered of a differential diagnosis in a patient presenting with foul-smelling unilateral nasal discharge. Proper anterior rhinoscopy with thudicum nasal speculum and good lighting should be carried out to reach the diagnosis. Early referral by the primary care practitioner to obtain an ENT consult should be the rule to avoid misdiagnosis and complications. Small-sized rhinoliths can be removed under local anaesthesia as outpatient, whereas larger ones require general anaesthesia to avoid complications such as perforation of the nasal septum or the hard palate.

References

1. Varley EW. Rhinolith: An incidental finding. *Br J Oral Surg.* 1964;2(1):40-3.
2. Davis O, Wolff A. Rhinolithiasis and maxillary antrolithiasis. *Ear Nose Throat J.* 1985;64(9):421-6.
3. Appleton SS, Kimbrough RE, Engstrom HI. Rhinolithiasis: A review. *Oral Surg Oral Med Oral Pathol.* 1988;65(6):693-8.
4. Carder HM, Hill JJ. Asymptomatic rhinolith: A brief review of the literature and case report. *Laryngoscope.* 1966;76(3):524-30.
5. Royal SA, Gardner RE. Rhinolithiasis: An unusual pediatric nasal mass. *Pediatr Radiol.* 1966;28(1):54-5.
6. Flood TR. Rhinolith: An unusual cause of palatal perforation. *Br J Oral Maxillofac Surg.* 1988;26(6):486-90.
7. Polson CJ. On rhinoliths. *J Laryngol Otol.* 1943;58:79-116.
8. Irfan M, Ramiza RR, Roselinda AR. Deciduous canine presented as a rhinolith in an adult. *The Internet Journal of Head and Neck Surgery.* 2008;2(2):7.
9. Irfan M, Hasme Zam H, Mohd Khairi MD. Unilateral foul smelly nasal discharge in an adult. *Malaysian Family Physician.* 2012;7(1):28-30.
10. Shah FA, George S, Reghunandan N. A case presentation of a large rhinolith. *Oman Med J.* 2010;25(3):230-1.