

The unusual traumatic locked young knee

Mohd Miswan MF, Latiff Alsagoff SNASA, Muhamad Effendi F, Ibrahim MI

Mohd Miswan MF, Latiff Alsagoff SNASA, Muhamad Effendi F, et al. The unusual traumatic locked young knee. *Malays Fam Physician*. 2019;14(2):26–28.

Keywords:

locked knee, arthroscopic, imaging

Authors:

Mohd Fairudz Mohd Miswan

(Corresponding author)

MS (Orth)

Surgical Sciences Cluster,
Faculty of Medicine,
Universiti Teknologi MARA,
Selangor, Malaysia

Sharifah Nor Amirah Syed Abdul Latiff Alsagoff

MBBS

Surgical Sciences Cluster
Faculty of Medicine
Universiti Teknologi MARA
Selangor, Malaysia.

Ferdhany Muhamad Effendi

MS (Orth)

Surgical Sciences Cluster
Faculty of Medicine
Universiti Teknologi MARA
Selangor, Malaysia.

Mohd Ikraam Ibrahim

MS (Orth)

Surgical Sciences Cluster
Faculty of Medicine
Universiti Teknologi MARA
Selangor, Malaysia.

Abstract

Locked knee is an orthopaedic condition requiring urgent treatment. Although the condition can be diagnosed via history, physical examination and imaging studies, the cause of the mechanical obstruction may only be apparent during arthroscopic examination of the knee joint. It is known that imaging plays a role in evaluating the integrity of intra-articular structures, however in some atypical cases, imaging cannot identify the definitive cause of locked knee. Here we report on two cases of locked knee, due to uncommon conditions which were unobservable via normal imaging studies.

Introduction

Locked knee is an incapacitating condition characterized by inability to achieve a full extension of the knee. It should be treated promptly and accordingly, because a prolonged locked position of the knee could result in contractures leading to flexion deformity. Subsequently, persistent weight bearing on a flexed knee will result in ineffective load distribution on the tibio-femoral articulation, thus promoting premature cartilage degeneration. Locked knee is caused by a mechanical obstruction from any intra-articular abnormalities. Common causes of locked knee include traumatic tear of the meniscus, cruciate ligament injuries and osteochondral fractures.¹ Magnetic resonance imaging (MRI) plays an important role in the initial work-up of a locked knee.² Apart from identifying the cause of the mechanical obstruction, an MRI can provide information about the pathology of other structures within the knee, such as a subchondral edema, cruciate ligament tears and the condition of the hyaline cartilage. With the advance in arthroscopic technique and instrumentation in the treatment of locked knee, open knee surgery is very rarely indicated. Here, we report on two atypical cases of locked knee with normal MRI findings.

Case 1

A 35-year-old male with no known prior medical condition presented with right knee pain and swelling 2 weeks after a trivial injury to the right knee. He twisted his knee while trying to avoid falling while walking

on a slippery floor. Initially he was treated by a general practitioner with oral analgesics and was advised to rest. Despite the partial resolution of the knee pain over the course of 2 weeks, he noticed that he was unable to fully straighten his right knee. There was no history of recurrent or multi-joint pain. Examination of the right knee revealed a mild effusion and generalized tenderness over the joint line. The range of motion was restricted to flexion of 30° to 100°. Radiographs of the knee did not reveal abnormalities. An MRI showed both medial and lateral meniscus was normal and the anterior and posterior cruciate ligaments were intact. A preoperative examination under anesthesia revealed similar physical findings. Subsequently, arthroscopy was performed. Unexpectedly, we discovered that the tibial plateau was covered by white 'chalky' material (**Fig. 1**). The synovium and both cruciate ligaments were intact, and there was no tear of the meniscus. Debridement of the whitish material was successfully performed during the arthroscopy. Intra-operatively, following the procedure, the right knee could be passively extended to 0°. Postoperatively, his recovery was uneventful and he was allowed to resume full-weight-bearing ambulation. A histological evaluation of the whitish material obtained intra-operatively showed monourate crystals, suggestive of tophi. Thereafter, he was started on urate-lowering therapy after a blood investigation revealed hyperuricemia at a level of 747 micromol/L. Follow up at 6 months showed no symptoms suggesting a recurrence. His knee range of motion was normal. Regular follow up with our rheumatologist was also arranged to monitor and further manage his hyperuricemia.

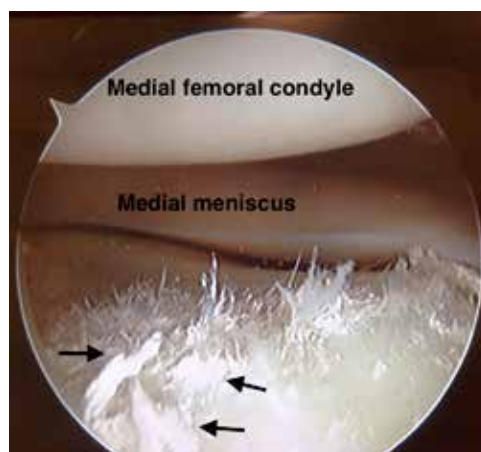


Fig. 1 Intra-arthroscopy photograph showing the medial tibial plateau deposits of white, 'chalky' material (black arrows).

Case 2

A 32-year-old male was reviewed at the clinic for painless locking of the right knee. He was seen initially in casualty 2 weeks prior to presentation for acute right knee pain and swelling. On that day, he sustained a twisting knee injury during a fall while trying to climb into his vehicle. Initial radiographs of the knee done in casualty did not reveal any bony injury, and he was allowed home with a slab to immobilize the knee. Upon removal of the slab during follow up at 2 weeks, he was unable to full extend his right knee, although the pain was significantly reduced. On examination, a mild effusion was noted, and the medial joint line was tender. The knee was fixed at 20° of flexion. The distal neurovascular status was intact. An MRI revealed no tear of the medial meniscus, and the cruciate ligaments were intact. During arthroscopy, it was revealed that the medial compartment of the knee was occupied with a well-defined ovoid soft tissue mass arising from the synovium (**Fig. 2**). The size of the mass was approximately 10mm x 5mm. The arthroscopic impingement test indicated the mass became impinged between the femoral condyle and the tibial plateau at 45° of knee flexion and full extension was not possible. After excision of the mass, full extension of the knee was achieved. Postoperatively, range of motion exercises were prescribed once the pain was tolerable. A histological evaluation of the excised mass revealed scattered multinucleated giant cells on a background of mononuclear fibroblasts,

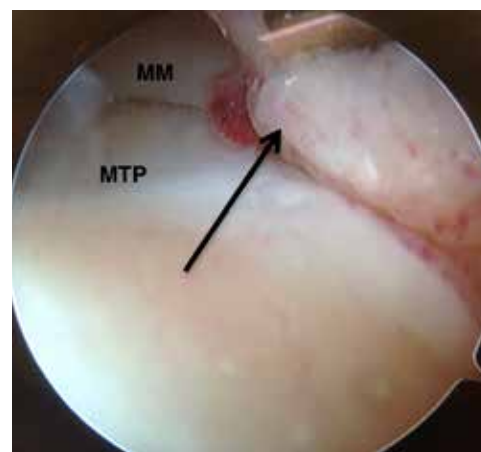


Fig. 2 Intra-arthroscopy photograph showing the tumor (black arrow) in the medial compartment of the knee. (MM = medial meniscus, MTP = medial tibial plateau.)

Discussion

Locked knee is an orthopaedic condition characterized by inability to fully extend the knee due to a displaced intra-articular structure.¹ The most common cause of locked knee is a bucket handle tear of the meniscus. Other causes include cruciate ligament injury, osteochondral fractures, osteoarthritis and synovial plicae.³ These conditions result in a loose fragment, which becomes entrapped between the femoral condyle and tibia plateau during extending movement of the knee, thus preventing full extension. Locked knee can be diagnosed accurately with adequate history and careful clinical examination. A definite history of injury, especially involving rotational and bending forces on the knee, and physical findings of joint line tenderness and effusion are notable features of locking due to mechanical obstruction.³ MRIs have been suggested to differentiate between 'true' locking and 'pseudo'locking, a condition in which the inability to fully extend the knee is due to pain or muscle spasms, and not a mechanical obstruction.⁴ In our practice, an MRI is performed to detect injury any other structures, such as the cruciate ligaments and the articular cartilage. This practice facilitates preoperative planning and allow us to counsel the patient regarding the procedures and postoperative rehabilitation.

Gouty arthropathy is characterized by hyperuricemia due to purine metabolism dysfunction. This hyperuricemic state results in the deposition of monosodium urate crystals in soft tissue and joints. Accumulation of this crystal also known as tophi, which,

in the knee joint, could lead to the formation of a loose body. It is a rare, but known cause of knee locking. However, evidence in the literature is scanty and consist mostly of case reports.^{5,6,7} MRI features of intra-articular tophi are heterogenous masses with intermediate intensity in both T1 and T2 weighted images. These masses are due mainly to the degree of calcification of the tophi.⁸ As with our patient (Case 1), a case has been reported previously in which an MRI performed preoperatively did not reveal these characteristic features.⁶ It is probable that the amount and degree of calcification of the tophi in our patient's knee was very minimal, thus it was not detected during the MR examination. As in our case, arthroscopic debridement has been successful in restoring full range of motion in most cases of locking due to intra-articular tophi.^{6,7}

LNS is a localized form of benign proliferative tumour arising from the synovium, for which the aetiology is not fully understood. Trauma, as well as allergic, toxic and genetic factors have been implicated in the pathophysiology of the condition.⁹ In our case (Case 2), the lesion arose from the synovium close to the medial compartment of the knee. This resulted in the mass becoming entrapped between the medial femoral condyle and medial tibial plateau, preventing full extension of the knee. Locked knee is one of the manifestation of this intra-

articular lesion, while other reported clinical features include knee instability, anterior knee pain and knee swelling.⁹⁻¹¹ MRI findings suggestive of LNS are non-specific. These include soft tissue masses with an iso- or hyperintense signal of T1 and variable signal intensity of T2 in weighted images. It is probable that the mass in our case was not detected due to its relatively smaller size as compared to others in the literature.¹² Although histologically similar to the more diffuse pigmented villonodular synovitis (PVNS), LNS lacks the feature of frond-like projections and significant hemosiderin deposition.¹² It is important to distinguish between the two forms of benign proliferative tumors because, while LNS is treatable by simple excision and has a low recurrence rate, PVNS warrants an extensive synovectomy due to its high recurrence rate.¹² Arthroscopic resection is recommended as the best treatment for LNS of the knee, except in cases of large-sized tumors, for which an arthrotomy may be required.⁹

Conclusion

These two cases illustrate atypical causes of locked knee with no identifiable pathology on MRI evaluation. Both were treated with an arthroscopic excision of the obstructing pathology and the patients had good functional outcome.

References

- Allum R, Jones J. The locked knee. *Injury* 1986;17(4):256-8.
- Acton D, Craig D. Should I scan or should I scope? *Knee* 2000;7(4):245-8.
- Bansal P, Deehan D, Gregory R. Diagnosing the acutely locked knee. *Injury* 2002;33(6):495-8.
- McNally E, Nasser K, Dawson S, Goh L. Role of magnetic resonance imaging in the clinical management of the acutely locked knee. *Skeletal Radiol* 2002;31(10):570-3.
- Chatterjee S, Ilaslan H. Painful knee locking caused by gouty tophi successfully treated with allopurinol. *Nat Clin Pract Rheumatol* 2008;4(12):675-9.
- Hussin P, Mawardi M, Nizlan N. The 'chalky culprit' of acute locked knee. *G Chir* 2014;35(9-10):239-40.
- Espejo-Baena A, Coretti S, Fernandez J, Garcia-Herrera J, Del P. Knee locking due to a single gouty tophus. *J Rheumatol* 2006;33(1):193-5.
- Chen C, Yeh L, Pan H, Yang C, Lu Y, Wang J et al. Intra-articular gouty tophi of the knee: CT and MR imaging in 12 patients. *Skeletal Radiol* 1999;28(2):75-80.
- Nau T, Chiari C, Seitz H, Weixler G, Krenn M. Giant-cell tumor of the synovial membrane: Localized nodular synovitis in the knee joint. *Arthroscopy* 2000;16(8):E22
- Otsuka Y, Mizuta H, Nakamura E, Kudo S, Inoue S, Takagi K. Tenosynovial giant-cell tumor arising from the anterior cruciate ligament of the knee. *Arthroscopy* 1996;12(4):496-9.
- Yoo J, Yang B, Park J. Localized nodular synovitis of the knee presenting as anterior knee pain: a case report. *Knee* 2007;14(5):398-401.
- Huang G, Lee C, Chan W, Chen C, Yu J, Resnick D. Localized nodular synovitis of the knee: MR imaging appearance and clinical correlates in 21 patients. *AJR Am J Roentgenol* 2003;181(2):539-43.